

# Prevalence of Microsporidian Spores Shed by Asymptomatic Lovebirds: Evidence for a Potential Emerging Zoonosis

Casey E. Barton, MS, David-N. Phalen, DVM, PhD, Dip ABVP (Avian), and Karen F. Snowden, DVM, PhD

**Abstract:** Several reports implicate *Encephalitozoon hellem*, a microsporidian parasite first described in humans and later in birds, as the causative agent of severe disease in immunocompromised patients. This study was conducted to assess the prevalence of microsporidian spores shed in the droppings of lovebirds. During a 7-month period, a total of 198 apparently healthy lovebirds from 8 flocks in Texas were sampled, including 113 peach-faced lovebirds (*Agapornis roseicollis*), 32 masked lovebirds (*Agapornis personata*), and 53 Fischer's lovebirds (*Agapornis fischeri*). Smears made from cloacal swab samples of individual birds were stained with calcofluor white M2R stain and examined for the presence of spores. Microsporidian spores were identified in the droppings of 25% of the lovebirds sampled. Peach-faced and masked lovebirds were more likely to shed spores than were Fischer's lovebirds ( $\chi^2 = 15.905$ ,  $P < .001$ ). No difference in spore shedding was found between juvenile and adult birds ( $\chi^2 = 0.157$ ,  $P = .692$ ; odds ratio = 1.659; 95% CI, 0.736–3.736). Lovebirds ( $n = 111$ ) were also assayed for psittacine beak and feather disease virus by polymerase chain reaction (PCR) testing of individual blood samples. Lovebirds that were PCR positive for psittacine beak and feather disease virus ( $n = 23$ ) were approximately 3 times more likely to shed microsporidian spores than were lovebirds that were PCR negative ( $\chi^2 = 3.981$ ,  $P = .046$ ; odds ratio = 2.6; 95% CI, 1.013–6.754). These results suggest that companion birds without obvious clinical illness commonly shed microsporidian spores. These birds may be a source of spore contamination for opportunistic infections in humans.

**Key words:** psittacine beak and feather disease virus, zoonotic disease, microsporidia, psittacine, lovebird, *Encephalitozoon hellem*, *Agapornis* species

## Introduction

Microsporidian organisms are obligate, intracellular, eukaryotic parasites found in a wide variety of vertebrate and invertebrate hosts. Over 100 genera and over 1200 species of microsporidian organisms have been described. In 1991, *Encephalitozoon hellem* was first described as the causative agent of severe ocular disease in 3 people who were positive for human immunodeficiency virus (HIV).<sup>1</sup> *Encephalitozoon hellem* has subsequently been identified as a cause of respiratory, urogenital, and disseminated systemic disease including sinusitis, keratoconjunctivitis, hepatitis, peritonitis, nephritis, and pneumonia in humans.<sup>1-3</sup>

Most of our knowledge about *E hellem* comes from studies in humans; however, *E hellem* infec-

tion has also been reported in birds. In 1997, *E hellem* was first reported in budgerigars (*Melopsittacus undulatus*).<sup>4</sup> Earlier case reports identified microsporidian organisms in psittacine birds but did not identify the parasite species. Fatal infections have been described in symptomatic individual birds or in isolated flock outbreaks. Peach-faced lovebirds (*Agapornis roseicollis*) are the most frequently reported hosts,<sup>5-8</sup> followed by masked lovebirds (*Agapornis personata*).<sup>9-11</sup> Microsporidian organisms also have been observed in a mixed flock of masked and Fischer's lovebirds (*Agapornis fischeri*),<sup>10</sup> in flocks of budgerigars,<sup>4,12</sup> and in eclectus parrots (*Eclectus roratus*),<sup>13</sup> double yellow-headed Amazon parrots (*Amazona ochrocephala*),<sup>14,15</sup> and a yellow-streaked lory (*Chalcopsitta scintillata*).<sup>16</sup> All case reports were domestic pet birds of unknown origin except for the yellow-streaked lory, which was wild caught in Indonesia and imported to Switzerland.

In 1998, the first microsporidian infection in a nonpsittacine bird was reported in an ostrich (*Stru-*

From the Department of Veterinary Pathobiology (Barton, Phalen, Snowden) and Schubot Exotic Bird Health Center (Phalen), College of Veterinary Medicine, Texas A&M University, Mailstop 4467, College Station, TX 77843-4467, USA.

*thio, camelus*).<sup>17,18</sup> Organisms were recently described in symptomatic wild hummingbirds<sup>19</sup> and in a Gouldian finch (*Erythrura gouldiae*).<sup>20</sup> *Encephalitozoon hellem* was confirmed in these birds by molecular analysis of a portion of the small subunit ribosomal RNA gene.<sup>18-20</sup> The identification of *E hellem* in nonpsittacine birds suggests that microsporidian organisms have a wider avian host range than previously believed.

*Encephalitozoon hellem* was reported in 2 unrelated eclectus parrots infected with psittacine beak and feather disease virus (PBFDV).<sup>13</sup> No specific relationship between this virus and microsporidian infection was speculated. The virus may be immunosuppressive to psittacine birds as suggested by frequent bursal and thymic lesions and by increased co-infections with secondary bacterial, chlamydial, viral, fungal, or protozoal organisms.<sup>21,22</sup> In humans, microsporidian infections are most frequently reported in immunosuppressed individuals.

Microsporidiosis is an emerging, opportunistic disease in immunocompromised individuals; therefore, recognizing and identifying these parasites and their potential host range are of increasing importance. The purpose of this study was to establish the presence and determine the prevalence of microsporidian spore shedding in a population of asymptomatic lovebirds. Because PBFDV is potentially immunosuppressive in birds, we also wanted to determine if a potential relationship exists between microsporidian spore shedding and PBFDV infection in this lovebird population.

## Materials and Methods

### Sample population

Three species of lovebirds (N = 198) were sampled for this study, including 113 peach-faced lovebirds, 32 masked lovebirds, and 53 Fischer's lovebirds. Lovebirds were selected by convenience sampling. Lovebirds were from 8 flocks from locations within a 500-mile radius in Texas. Four flocks (2 pet stores, 1 hobbyist's aviary, and 1 wholesaler) contained both peach-faced and masked lovebirds. Three of these 4 flocks maintained other species of birds. Two flocks, from a research facility and a hobbyist's aviary, exclusively contained peach-faced lovebirds. Two flocks, from a wholesaler and a private, closed aviary, contained peach-faced, masked, and Fischer's lovebirds. Both of these flocks maintained other psittacine bird species.

Samples from lovebirds were collected over a 7-month period in 1999. All surveyed birds appeared healthy at the time of sampling. Birds were separated into 2 groups: juvenile birds (dark beaks),

which included birds less than 6 months of age, and adult birds (pale beaks), which included birds over 6 months of age.

### Sample collection

Cloacal swab samples were collected with polyester-tipped applicators (Puritan Sterile Dacron Polyester tipped applicators 25-800D, Hardwood Products Company, Guilford, ME, USA) to make 2-cm smears on duplicate slides for staining and microscopic examination. Slides were allowed to air dry and were stored at room temperature until they were stained and evaluated. Minimal discomfort to birds and minor manual restraint was involved with bird handling and sample collection. The University Laboratory Animal Care Committee and the Clinical Research Review Committee approved the animal-use protocols.

**Parasite detection:** The calcofluor white M2R (Sigma Chemical Company, St Louis, MO, USA) staining method was used as the primary screening technique.<sup>23</sup> Calcofluor white M2R was prepared as a 0.5% (wt/vol) solution in phosphate-buffered saline (PBS, pH = 7.4), stored in the dark at room temperature, and centrifuged before use (940g for 10 minutes twice) to remove precipitates. Slides were fixed in 100% methanol for 5 minutes. Methanol fixed smears were calcofluor stained for 3 minutes at room temperature in the dark, rinsed with PBS, and counterstained with 0.1% Evans Blue (Sigma) in PBS for 1 minute at room temperature. Slides were rinsed again in PBS followed by distilled water and were air dried in the dark. Calcofluor-stained slides were viewed under  $\times 1000$  oil magnification with an ultraviolet microscope (Nikon Labphot2 microscope [Nikon Instruments, Melville, NY] with epifluorescent lighting; excitation filter, 380-420 nm; emission wavelength, 430 nm). Positive controls for the calcofluor staining were smears made from culture-derived *E hellem* spores. Organisms appeared as bluish white or turquoise oval halos and were 1.5-2.0  $\mu\text{m}$  by 2.5-3.0  $\mu\text{m}$  (Fig 1). The number of spores were quantified and classified as follows: 1) low parasite burden =  $<10$  spores per slide, 2) intermediate parasite burden = 1 spore in several fields and  $>10$  spores total, and 3) high parasite burden =  $\geq 1$  spore in most fields viewed.

**PBFDV detection:** At the same time cloacal swab samples were collected, blood samples were collected by jugular venipuncture from a subset of lovebirds. Blood samples were stored at 4°C in heparinized containers (Capiject T-MLH heparinized tubes; Terumo, Elkton, MD, USA) and submitted

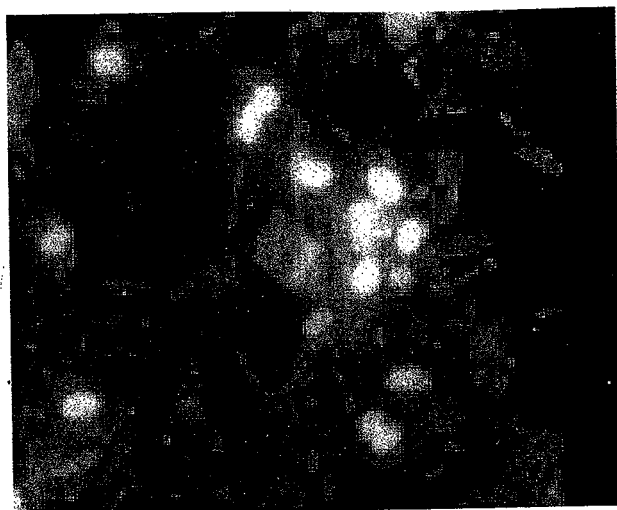


Figure 1. Sample identifying microsporidian parasites in a lovebird's droppings (calcofluor,  $\times 1000$ ).

within 2 days of collection to a commercial laboratory (Research Associates Laboratory, Milford, OH, USA) for PBFVDV testing by polymerase chain reaction (PCR).

**Data analysis:** The SAS program v6.12 (SAS Inc, Cary, NC, USA) was used for data analysis. The prevalence of microsporidian spore shedding in the total sample population of lovebirds was calculated. Prevalence was also calculated for each lovebird species and for each of the 8 flocks. For this study, prevalence was defined as the proportion of lovebirds shedding microsporidian spores as determined by calcofluor staining over the 7-month sampling period in Texas. The overall prevalence and flock prevalence of PBFVDV were also determined. The relationship between the fecal shedding of microsporidian spores and the independent variables of lovebird species, animal age, and concurrent infection with PBFVDV was assessed with the

Table 1. Prevalence of microsporidian shedding in 8 flocks of lovebirds in Texas during a 7-month period in 1999.

Flock	Positive (n)	Sample size (n)	Prevalence (%)
1	16	59	27
2	5	20	25
3	1	7	14
4	5	10	50
5	2	19	11
6	1	41	2
7	12	35	34
8	7	7	100
Total	49	198	25

chi-square statistic and the odds ratio (OR) method. Peach-faced lovebirds were used as the reference category for species analysis because this group was the largest sample size in this survey. The OR measured strength of association between the dependent variable, fecal shedding of spores, and each independent variable. An OR is statistically significant only when the 95% confidence interval (CI) does not include 1. Significance level ( $\alpha$ ), the probability of falsely rejecting the null hypothesis that there was no statistical association between fecal spore shedding and each of the independent variables, was set at  $< .05$ .

## Results

### Microsporidian spore shedding in lovebirds

**Prevalence in lovebird sample population:** Microsporidian spores were identified in the droppings of apparently healthy lovebirds. The prevalence of spore shedding as detected by calcofluor staining of cloacal smears in this population of asymptomatic birds was 25% (49 of 198) (Fig 1; Table 1). Every flock contained at least 1 microsporidia-positive bird (Table 1). The individual flock prevalence ranged from 2% to 100%. Of the microsporidia-positive lovebirds, 47% (23 of 49) had a low parasite burden, 41% (20 of 49) had an intermediate parasite burden, and only 12% (6 of 49) had a high parasite burden.

**Lovebird species versus microsporidian shedding:** The prevalence of spore shedding was 29% (33 of 113) in the peach-faced lovebirds, 41% (13 of 32) in the masked lovebirds, and 6% (3 of 53) in the Fischer's lovebirds. Microsporidian spore shedding was statistically associated with lovebird species ( $N = 198$ ;  $P < .001$ ). Both peach-faced and masked species had an increased probability of spore shedding compared with Fischer's lovebirds. No significant difference in spore shedding was detected between peach-faced and masked lovebirds. Fischer's lovebirds were 11.4 times less likely to shed microsporidia than were masked lovebirds (OR = 0.088; 95% CI, 0.026–0.291) and were 6.9 times less likely to shed microsporidia than were peach-faced lovebirds (OR = 0.145; 95% CI, 0.048–0.439).

**Lovebird age versus microsporidian shedding:** Twenty-two percent (13 of 59) of juvenile lovebirds and 20% (22 of 113) of adult lovebirds were parasite positive. Age was not determined for 26 lovebirds. There was no statistical association between parasite spore shedding and age of the infected bird ( $n = 172$ ;  $P > .05$ ).

**Table 2.** Flock prevalence of psittacine beak and feather disease virus in lovebirds as determined by PCR testing of serologic samples.

Flock	Positive (n)	Total sampled (n)	Prevalence (%)
1	8	22	36
2	8	12	67
3	0	7	0
4	1	10	10
5	—	—	—
6	5	26	19
7	1	34	3
8	—	—	—
Total	23	111	21

*Species identification:* Parasites were collected from the droppings of a single peach-faced lovebird originating from a wholesaler's flock used in this study. An isolate was established in tissue culture, and the parasite was identified as *E hellem* genotype I (the most frequently reported genotype of human isolates) by molecular analysis of the small subunit ribosomal RNA gene as previously reported.<sup>24</sup>

#### Microsporidian shedding and PBFVDV test status

Twenty-one percent (23 of 111) of lovebirds surveyed for PBFVDV were virus positive (Table 2). The individual PBFVDV flock prevalence ranged from 0 to 67%, and 5 of the 6 lovebird flocks surveyed contained virus-positive birds (Table 2). The chi-square test for microsporidian shedding versus PBFVDV infection showed that microsporidia and PBFVDV results may be dependent ( $n = 111$ ;  $P = .046$ ) (Table 3). Lovebirds concurrently infected with PBFVDV were approximately 3 times more likely to shed microsporidian spores (OR = 2.6; 95% CI, 1.013–6.754) (Table 3).

#### Discussion

In this study, the overall prevalence of microsporidian shedding in 3 species of lovebirds from 8 flocks in Texas was 25%. At least 1 parasite-positive bird was found in each of the 8 flocks examined. Peach-faced and masked lovebirds were significantly more likely to shed parasites than were Fischer's lovebirds. In previous reports of microsporidian infections in birds, peach-faced and masked lovebirds were the most frequently reported species.<sup>5–11</sup> Our results suggest that microsporidian infections are more common in lovebirds than previously recognized.

Before this study, all previously reported micro-

**Table 3.** Microsporidian shedding in relation to PCR test results for psittacine beak and feather disease virus (PBFVDV) in lovebirds ( $n = 111$ ) from 8 flocks in Texas sampled over a 7-month period in 1999.<sup>a</sup>

Microsporidia	PBFVDV		Total
	PCR + (%)	PCR - (%)	
+	10 (9)	20 (18)	30
-	13 (12)	68 (61)	81
Total	23 (21)	88 (79)	111

<sup>a</sup> Significance at  $P < .05$  by chi-square test ( $\chi^2 = 3.981$ ,  $P = .046$ ); odds ratio = 2.6 (95% CI, 1.013–6.754).

sporidian infections were in birds with clinical disease. To date, no studies have recognized a commensal association of microsporidian parasites in avian hosts. In other words, no microsporidian species have been identified as avian parasites. Therefore, it is important to determine if these organisms are true avian parasites or if reported infections were sporadic occurrences. In this epidemiological study, we describe microsporidian infections in apparently healthy lovebirds for the first time.

To date, the only microsporidian parasite identified in birds has been *E hellem*.<sup>5–16</sup> An increasing number of avian species have been identified as hosts for this parasite, including psittacine, ratite, and passerine species. These species originate from natural habitats in Africa, the South Pacific, and South America. These data support the cosmopolitan distribution of *E hellem* in many different species of birds throughout the world and indicate that it is probably a natural parasite in these birds.

In contrast, the medical community currently identifies *E hellem* as a human pathogen causing respiratory or ocular disease primarily in immunocompromised patients. However, sources of these infections have not been established. Our documentation of spore shedding in asymptomatic birds raises the concern of the potential for zoonotic transmission between birds and humans. Birds from 7 of the 8 facilities tested in this study were available for sale to the general public. Infected pet birds shed spores into the environment in their droppings and thus may provide a source of infection for other birds and potentially for humans. A supporting observation is that several patients with AIDS with *E hellem*-associated keratoconjunctivitis owned or were exposed to pet birds.<sup>16,25</sup> This topic is extremely important in terms of public health implications. Veterinarians and physicians working with immunocompromised individuals who are exposed to lovebirds should discuss this potential zoonotic risk with those clients.

Because microsporidian infections are more prevalent in immunosuppressed humans, we sought to determine whether PBFDV infection, which is speculated to cause immunosuppression in birds, would have an impact on the prevalence of microsporidian infection in birds. An OR analysis concluded that lovebirds currently infected with PBFDV were approximately 3 times more likely to shed microsporidian spores. These data suggest that immunosuppression may play a role in parasite shedding. This association is strengthened by the previous observation that 2 eclectus parrots with systemic microsporidiosis were also infected with PBFDV.<sup>13</sup>

The surprisingly high prevalence of PBFDV in the lovebird aviaries we surveyed may have important implications for aviculturalists, bird retailers, and avian veterinarians. Five of the 6 lovebird flocks contained virus-positive birds with an overall prevalence of 21%. Our data indicate that lovebirds may be an important source of PBFDV in pet stores and aviaries, suggesting that the birds would pose a significant risk of infection for other susceptible bird species.

Previous studies in birds indicate that microsporidian parasites multiply in tissues in the kidneys, intestines, or both; therefore, microsporidian spores may be shed in feces or urine.<sup>9,12-14</sup> In this study, we used cloacal swab samples because this technique allowed for a rapid and easy sampling of both feces and urine from individual lovebirds. However, the sensitivity of detecting spores in cloacal swabs is unknown. Potential limitations to the use of cloacal swabs for parasite sampling include nonuniform smears and varying sample quantities from each bird. It is possible that a single sample may not detect infection in all birds, especially those shedding low numbers of spores. Future investigations evaluating repeated samples from individual birds may be useful. Comparisons of cloacal swabs and smears from droppings as sampling methods are also needed.

The "gold standard" for microsporidian detection is transmission electron microscopy. Because this is not a convenient method for processing large numbers of samples, the calcofluor method was developed as a rapid and easy test to use for screening diagnostic purposes. The calcofluor staining method used to examine the swab samples was similar to the method used for parasite detection in human body fluids and feces (Fig 1).<sup>23</sup> However, this stain is not readily available in veterinary diagnostic facilities because it requires a fluorescent microscope that emits a specific wavelength of light that differs from a standard fluorescent wavelength. For veterinary diagnostic purposes, it is recommended to

submit methanol-fixed cloacal smears, formalin-fixed droppings, or both to an experienced veterinary or human diagnostic laboratory for special staining.

Our results demonstrate that microsporidian infections may be widespread in asymptomatic lovebirds. Results of our survey are consistent with previous case reports and implicate birds as a possible primary host for *E hellem*. The high prevalence of spore shedding in this population of lovebirds suggests that bird droppings may be a potential environmental source of *E hellem* infection in humans. Veterinarians should become familiar with this organism and its epizootiology to properly advise and educate their clients about the potential public health significance. Because microsporidiosis is an emerging opportunistic disease of humans and their companion animals, recognizing and identifying these parasites and their potential host range are of increasing importance.

*Acknowledgments:* We thank the participants in this survey who allowed us to collect samples from their bird collections. This research was funded in part by NIH grant RO3 AI 45377.

## References

1. Didier ES, Didier PJ, Friedberg DN, et al. Isolation and characterization of a new human microsporidian, *Encephalitozoon hellem* (n. sp.), from three AIDS patients with keratoconjunctivitis. *J Infect Dis.* 1991; 163:617-621.
2. Kotler DP, Orenstein JM. Clinical syndromes associated with microsporidiosis. In: Wittner M, ed. *The Microsporidia and Microsporidiosis*. Washington, DC: ASM Press; 1999:258-292.
3. Friedberg DN, Ritterband DC. Ocular microsporidiosis. In: Wittner M, ed. *The Microsporidia and Microsporidiosis*. Washington, DC: ASM Press; 1999: 293-324.
4. Black SS, Steinhort LA, Bertucci DC, et al. *Encephalitozoon hellem* in budgerigars (*Melopsittacus undulatus*). *Vet Pathol.* 1997;34:189-198.
5. Novilla MN, Kwapien RP. Microsporidian infection in the pied peach-faced lovebird (*Agapornis roseicollis*). *Avian Dis.* 1978;22:198-204.
6. Lowenstine LJ, Petrak ML. Microsporidiosis in two peach-faced lovebirds. In: Montali RJ, Migaki G, eds. *The Comparative Pathology of Zoo Animals*. Washington, DC: Smithsonian Institution Press; 1980: 365-368.
7. Branstetter DG, Knipe SM. Microsporidian infection in the lovebird *Agapornis roseicollis*. *Micron.* 1982; 13:61-62.
8. Norton JH, Prior HC. Microsporidiosis in a peach-faced lovebird (*Agapornis roseicollis*). *Aust Vet J.* 1994;71:23-24.
9. Kemp RL, Kluge JP. *Encephalitozoon* sp. in the blue-

- masked lovebird, (*Agapornis personata*): first confirmed report of microsporidian infection in birds. *J Protozool.* 1975;22:489-491.
10. Randall CJ, Lees S, Higgins RJ, Harcourt-Brown NH. Microsporidian infection in lovebirds (*Agapornis* spp.). *Avian Pathol.* 1986;15:223-231.
  11. Powell S, Tang K, Chandler F, et al. Microsporidiosis in a lovebird. *J Vet Diagn Invest.* 1989;1:69-71.
  12. Daft B, Kinde H. Microsporidiosis in nestling budgerigars (*Melopsittacus undulatus*). *Proc Reg Meet California Vet Path.* 1989;1-5.
  13. Pulparampil N, Graham D, Phalen D, Snowden K. *Encephalitozoon hellem* infection in two eclectus parrots (*Eclectus roratus*): identification from archival tissues. *J Eukaryot Microbiol.* 1998;45:651-655.
  14. Poonacha KB, William PD, Stamper RD. Encephalitozoonosis in a parrot. *J Am Vet Med Assoc.* 1985;186:700-702.
  15. Canny CJ, Ward DA, Patton S, Orosz SE. Microsporidian keratoconjunctivitis in a double yellow-headed Amazon parrot (*Amazona ochrocephala oratrix*). *J Avian Med Surg.* 1999;13:279-286.
  16. Suter C, Mathis A, Hoop R, Deplazes P. *Encephalitozoon hellem* infection in a yellow-streaked lory (*Chalcopsitta scintillata*) imported from Indonesia. *Vet Rec.* 1998;143:694-695.
  17. Gray ML, Puette M, Latimer KS. Microsporidiosis in a young ostrich (*Struthio camelus*). *Avian Dis.* 1998;42:832-836.
  18. Snowden K, Logan K. Molecular identification of *Encephalitozoon hellem* in an ostrich. *Avian Dis.* 1999;43:779-782.
  19. Snowden K, Daft B, Nordhausen RW. Morphological and molecular characterization of *Encephalitozoon hellem* in hummingbirds. *Avian Pathol.* 2001;30:259-263.
  20. Carlisle MS, Snowden K, Gill J, et al. Microsporidiosis in a Gouldian finch (*Erythrura [Chloebeia] gouldiae*). *Aust Vet J.* 2002;80:41-44.
  21. Latimer KS, Rakich PM, Niagro FD, et al. An updated review of psittacine beak and feather disease. *J Assoc Avian Vet.* 1991;5:211-219.
  22. Todd D. Circoviruses: immunosuppressive threats to avian species: a review. *Avian Pathol.* 2000;29:373-394.
  23. Didier ES, Orenstein JM, Aldras A, et al. Comparison of three staining methods for detecting microsporidia in fluids. *J Clin Microbiol.* 1995;33:3138-3145.
  24. Snowden KF, Logan K, Phalen DN. Isolation and characterization of an avian isolate of *Encephalitozoon hellem*. *Parasitology.* 2000;121:9-14.
  25. Orenstein JM, Seedor J, Friedberg DN, et al. Epidemiologic notes and reports: Microsporidian keratoconjunctivitis in patients with AIDS. *MMWR Morb Mortal Wkly Rep.* 1990;39:188-189.