

# the ITCH

## Dermatology Team

Department of  
Small Animal  
Clinical Sciences

Alison Diesel,  
DVM, DACVD

Adam P. Patterson,  
DVM, DACVD

Amanda Friedeck,  
BS, CVA

Department of  
Veterinary Pathobiology

Joanne Mansell,  
DVM, MS, DACVP

Aline Rodrigues,  
DVM, MS, DACVP

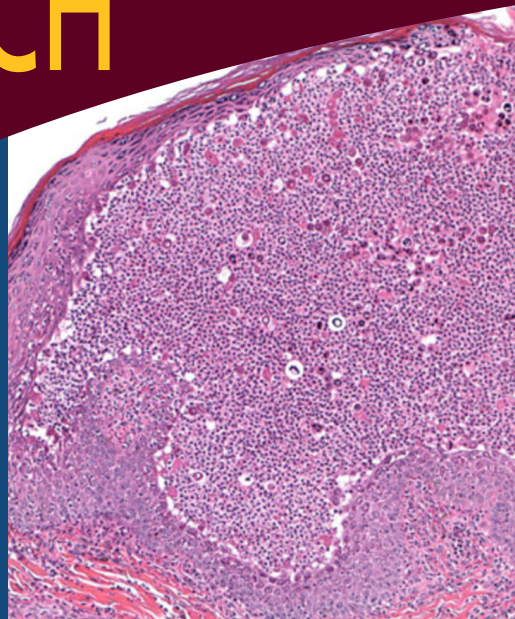
## Clinical Appointments

Small Animal  
Dermatology  
979-845-2351

Equine Dermatology  
979-845-3541

For more  
information, please  
visit our website at:

[vetmed.tamu.edu/  
services/dermatology](http://vetmed.tamu.edu/services/dermatology)



## Submitting Skin Biopsies

- The species, age, sex, and breed of the patient should always be given.
- Always submit a brief summary of the patient's history as well as treatments given. Distribution (or site, if the lesion is focal) of the clinical lesion(s) is very important, as is the location of the sites from which the biopsies were taken.
- Describe the lesion you are sampling; this will alert the pathologist to order additional sections if the lesion you describe does not appear on the slide she or he receives.
- If possible, submit digital or printed images of your patient to the pathologist with the biopsies.
- Your clinical impressions and your working clinical diagnosis should be given.
- Coming to a final diagnosis is a cooperative effort between the clinician and the pathologist so give your pathologist the best history you can, and don't hesitate to call your pathologist with any questions you may have.

## The Pathologist's View: How and when to take a biopsy

Lesions in the skin progress from "early" to "fully developed" to "late". The most diagnostic lesion is a fully developed lesion as it increases the likelihood of a definitive diagnosis for your patient. It is important to examine all lesions on the patient to find some that are in this stage. The clinical appearance of fully developed lesions includes macules, patches, papules, pustules, vesicles, bullae, cysts, comedones, wheals, plaques, and nodules. Late lesions are usually the result of end stage pathological processes, infections, and/or self-trauma, and include scales, crusts, erosions, ulcers, and fissures. These should be avoided unless earlier lesions are not present since they are less diag-

nostic than a fully developed lesion. Unless you are taking a biopsy from a solitary or localized lesion, biopsies of multiple lesions should be submitted (at least 3 punches) to give the pathologist as much tissue as possible to make a diagnosis.

Trimming the hair with scissors at the site of the proposed biopsy site is greatly preferable to shaving the hair, as shaving will remove the stratum corneum and any crusts or scale in the area; these structures are needed by the pathologist. Gently wash the area and pat dry. It

helps the pathologist if a line is drawn with an indelible marker on the skin before taking the biopsy, in the direction of hair growth (Fig-

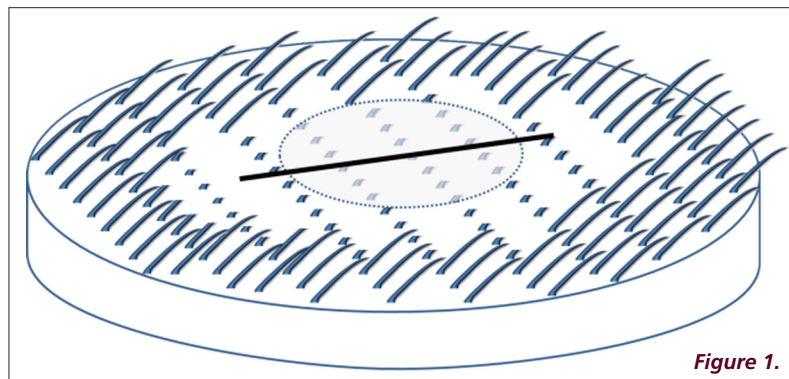


Figure 1.



## Did you know?

- The VMTH has two dermatopathologists who are Diplomates of the American College of Veterinary Pathologists, Dr. Joanne Mansell and Dr. Aline Rodrigues, who work closely with dermatologists, Dr. Adam Patterson and Dr. Alison Diesel in the diagnosis of your pet's skin disease at Texas A&M's Veterinary Medical Teaching Hospital.
- Dr. Mansell and Dr. Rodrigues also run the Dermatopathology Specialty Service, a mail-in service for any veterinary practitioners or dermatologists. They offer specialized evaluation of your skin biopsies from clinics all over the US.
- Details, downloadable submission forms, and submission instructions for the Dermatopathology Specialty Service can be found at <http://vetmed.tamu.edu/vtpb/professional-services/dermatopathology>.





Figure 2.

ure 1), especially if the patient has light colored hair, since skin biopsies are trimmed for processing parallel to the direction of the hair follicles (Figure 2) allowing for the entire length of the follicles to be examined (Figure 3). Thus if a line is present, the technician trimming the biopsy can easily see the orientation. Punch biopsies are the standard method of taking biopsies in dermatology. Larger-sized punch biopsies (6-8mm) are preferred unless the biopsies are from a site in which a smaller size is required (e.g., nasal planum, paw pads, periorcular skin). Elliptical (excisional) biopsies can be used on large bullae or pustules that are too big for a punch biopsy. Wedge biopsies are useful for raised nodular lesions, and ear margins or footpad margins. If you want the gradient of diseased to normal appearing skin examined, then an elliptical or wedge biopsy is mandatory. In general the pathologist does not need normal skin unless the clinician specifically wants to compare one site to another. Once taken, punch biopsies should be immediately immersed in 10% buffered formalin. Elliptical biopsies should be placed with the subcutaneous side down and adhered to a piece of cardboard or tongue depressor before immersion in formalin to prevent the skin from curling up on itself. 🇺🇸

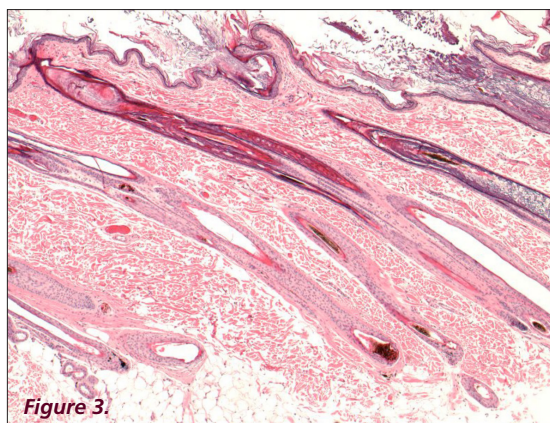


Figure 3.

## Should I use a dermatopathologist for my skin biopsies ?

There are many excellent pathologists in diagnostic pathology, and the question often comes up as to whether you should use a dermatopathologist or a general pathologist for your skin biopsies. There are several factors to consider.

Dermatopathologists are pathologists with specialized knowledge and skills in the histopathology of skin diseases and these pathologists are likely your best bet for getting the most out of your skin biopsies. There are at least 300 diseases that can be recognized histologically in the skin making it a complicated and time consuming organ for the pathologist to examine, and therefore it is important to use a pathologist who has a major interest in skin and has the time to spend evaluating skin biopsies, even if they are not a designated dermatopathologist. Practitioners should recognize that there are often secondary processes present in skin diseases, particularly secondary pyodermas, and so evaluating skin biopsies can be complex.

If you are not sure if your lab has a dermatopathologist or pathologist with an interest in skin on staff, call the lab and ask. Another factor to consider is that fast turn-around labs sometimes use short-cycle tissue processing machines that are not ideal for processing skin, so if you use one of these labs call and see if your biopsies can be put on a regular cycle tissue processor.

Lastly, communication between the practitioner and the pathologist is very important, so choose a pathologist who you are comfortable calling to discuss your case, and who will return your phone calls. 🇺🇸